Red, White, and Ulcerative Lesions of the Oral Cavity. What are They? How to Treat?

Susan Müller, DMD, MS, Professor
Department of Pathology
Department of Otolaryngology
Winship Cancer Institute
Emory University School of Medicine

Questions to think about when evaluating oral lesions

- Acute vs Chronic
- Multiple vs Single
- Location
- Duration
- Associated pain
- Induration

- Other mucosal lesions
- Cutaneous lesions
- Systemic diseases
- Medications
- Any known triggers

What is Oral Leukoplakia?

- Leukoplakia is the most common *oral precancer* (potentially malignant oral lesion)
- 2.6% worldwide prevalence
- 70-95% of oral leukoplakias will not progress to malignancy
- Lesions of long duration have a greater risk of malignant transformation than those of short duration

What is *NOT* Oral Leukoplakia?

- A clinical diagnosis dependent on the exclusion of other lesions that present as white plaques:

cheek/tongue biting
lichen planus
drug reaction
aspirin burn
cinnamon reaction
candidiasis
leukoedema
tobacco pouch keratosis
amalgam reaction
geographic tongue

Cheek Biting

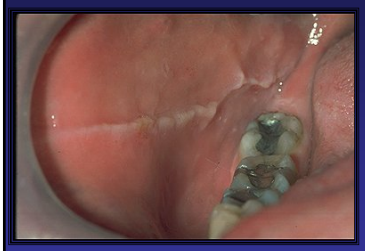

Linea alba associated with pressure, friction, or sucking trauma seen along the occlusal plane

Smokeless Tobacco

- Smokeless tobacco keratosis has a much smaller risk of developing cancer than oral leukoplakia that develops in tobacco smokers.
- Smokeless tobacco keratosis, after habit cessation, is routinely reversible.

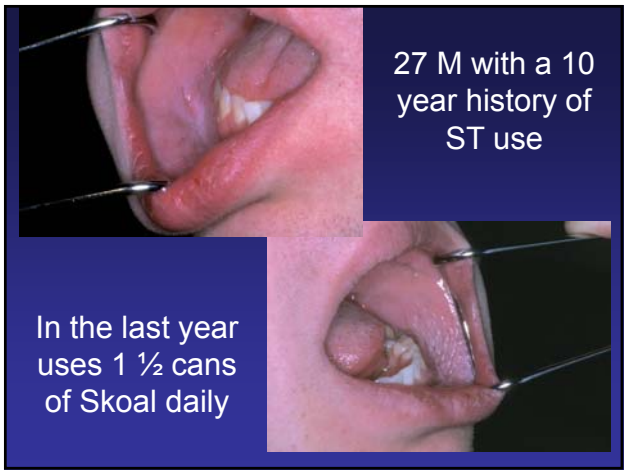

Sites of Oral Leukoplakia

- More than 2/3 or oral leukoplakia are found at 3 sites: lip vermilion, gingiva, and buccal mucosa
- Sites where leukoplakia are most likely to be associated with pre-cancer/cancer:
  tongue, lip vermilion and floor of mouth
  (account for 93% of all leukoplakia associated with dysplasia or cancer)

Erythroplakia

- A red patch that cannot be clinically diagnosed as any other condition.
- Must exclude other red lesions:

mucositis	*drug reaction*
candidiasis	*aphthae*
herpes	*non-specific ulcer*
hemangioma	*pyogenic granuloma*

Nicotine Stomatitis

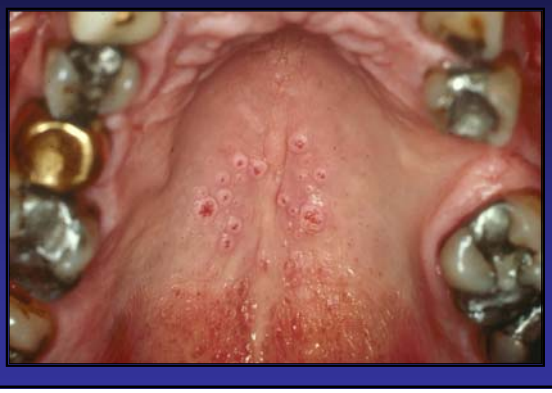

Erythroplakia

- Usually asymptomatic, and appears as a well-demarcated, erythematous macule or plaque with a soft velvety texture.
- Almost all (90%) of erythroplakia exhibit high grade dysplasia, carcinoma-in-situ, or invasive carcinoma.

Erythroleukoplakia

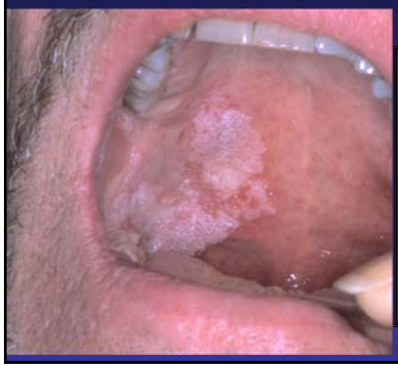

Pre-malignant lesion that has both a leukoplakic (white), and erythroplakic (red) component.

HPV and Saliva Testing

- At this time we don't know how a +saliva test translates into cancer risk and patient management.
- Creates unnecessary anxiety
- We are uncertain what the natural history of oral HPV infection is and no management protocols have been established.

Oral Lichen Planus

Common chronic immunologically mediated mucocutaneous disorder
Middle age
Female predilection – 3:2
Prevalence
Cutaneous 1%
Oral 0.1% - 2.2%

- Reticular form
  - Most common
  - asymptomatic
  - Wickham's striae
  - Bilat BM, tongue, gingiva, palate, vermilion border
- Plaque form
  - Dorsal tongue

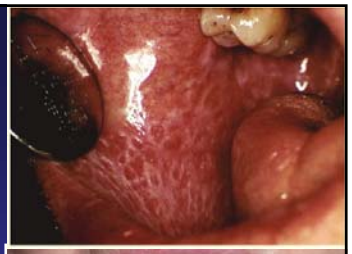

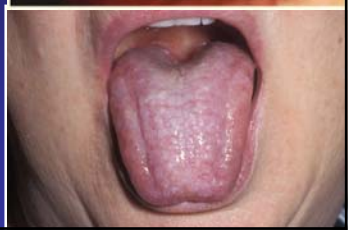

Erosive OLP:

- less common
- symptomatic
- Atrophic erythematous areas with central ulceration
- bordered by fine, white radiating striae

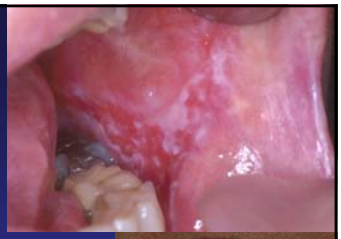

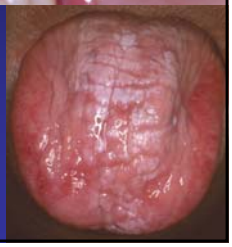

Treatment of Erosive OLP

100 mg doxycycline qd for 90 days
Decadron elixir:
0.5 mg/ 5ml
Disp 500 ml
1 tsp qid, hold 3m, spit out, no food/liquid for 30m
Severe – systemic prednisone

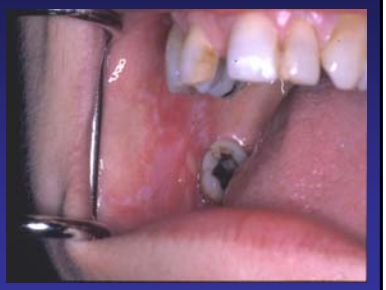

Lichen Planus

- **Is Lichen Planus a premalignant lesion?**
- Controversial: reported frequency of 0.4% to 5% over observation period of .5 to > 20 yrs.
- Most occur in sites of atrophic or erosive LP
- In some reported cases, LP diagnosis made only on clinical observation.
- The clinical manifestations and treatment of oral lichen planus. Dermatologic Clinics, 21;January 2003.

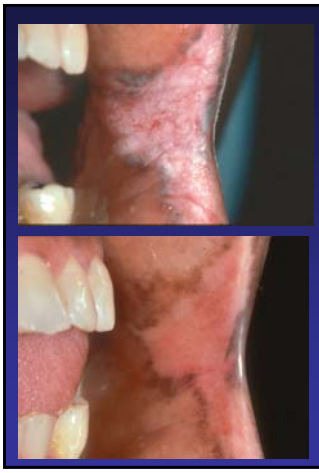

Cinnamon Reaction

Contact reaction to cinnamon flavoring found in gum, candy, toothpaste, mouthwash, dental floss, soft drinks.

Can see thickened white areas as well as red, sore areas.

Possible Causes of a Burning Mouth

- Allergy
- Mechanical Irritation
- Infection
- Myofascial pain
- Oral habits
- Geographic tongue
- Menopause
- Esophageal reflux
- Acoustic neuroma
- Vitamin deficiency
- Diabetes
- Xerostomia
- Medication
- Psychogenic factors

Epidemiology of BMS

- Post/peri-menopausal female
- 18-75 yrs (mean 59 yrs)
- Reported prevalence of 5.1% in general dental practice population
- Duration of symptoms 3-6 yrs
- Associated symptoms:
  - Headaches
  - Sleep disturbances
  - Anxiety, depression
  - Neuroses

Epidemiology of BMS

- 92% - report more than one site
- 43% - taste disturbance
- 59% - milder after waking
- 75% - worse in the evening
- 61% - parafunctional habits

Sites of Discomfort in BMS

- **Tongue** – most affected site
- Anterior hard palate
- Lips
- Gingiva
- Throat

Least frequent

Treatment of BMS

Benzodiazepine: Clonazepam .5-1.0mg
Tricyclic antidepressant: Elavil 25-50mg
Pamelor 20-50 mg
Gabapentin: Neurontin ????
Topical capsaicin: local desensitization
Alpha lipoic acid: 600 mg daily

Geographic Tongue

Clinical lesions generally present on the anterior two-thirds of the dorsal tongue as multiple, well-demarcated zones of erythema due to atrophy of the filliform papillae. These zones may be surrounded by a white circinate border.

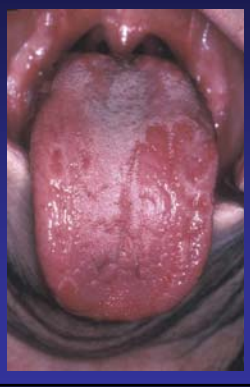

Oral Candidiasis

- An opportunistic organism which tends to proliferate with the use of broad-spectrum antibiotics, corticosteroids, cytotoxic agents and medications that reduce salivary output

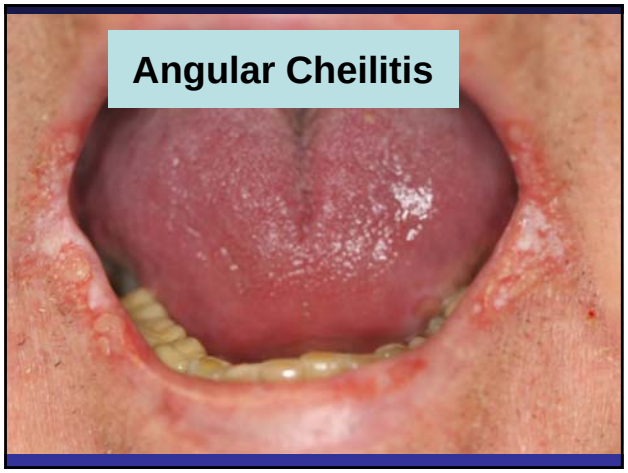

Steroid Inhaler Can Cause Oral Candidiasis

Treatment

- Nystatin Suspension 5mg/ml
  Dispense 240 ml; 1tsp qid
- Clotrimazole (Mycelex) 10 mg Troche
  One troche by mouth 5x daily for 14 d
- Fluconazole 100mg QD 14 days
- Mycostatin or Nizoral ointment
- Mycolog II

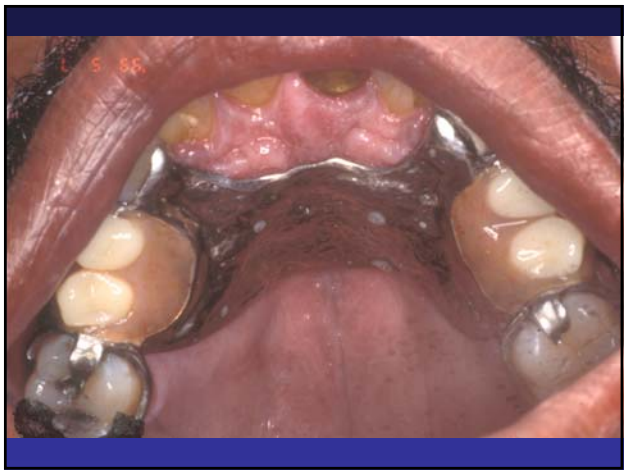

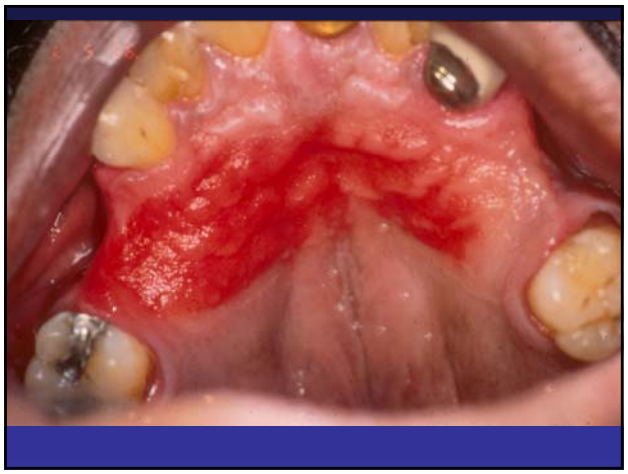

Remember to Treat the Denture!

- Patient should be encouraged to remove denture when sleeping
- Place an antifungal cream (eg clotrimazole) inside the denture QD for 30 days.

Hairy Tongue

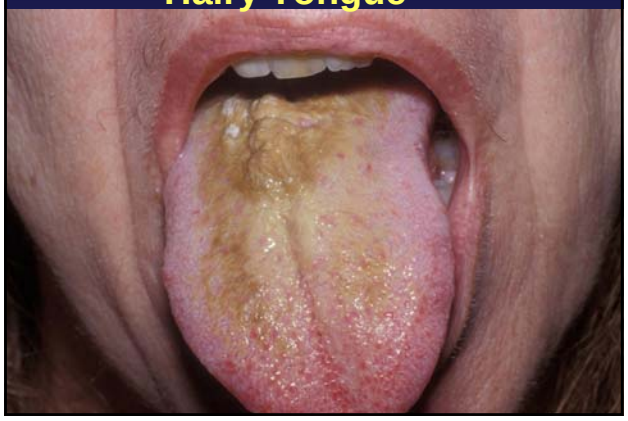

Aphthous Ulcers

Aphthous Ulcer - Triggers

1. Primary immunodysregulation
   Behcets, Crohns, celiac disease, cyclic neutropenia, AIDS, stress
2. Decrease in the mucosal barrier
   Trauma,pernicious anemia
3. Increase in antigenic exposure
   Foods, flavoring agents

Recurrent Orolabial HSV1

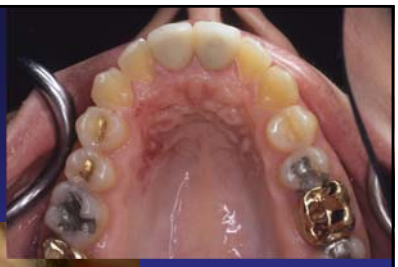

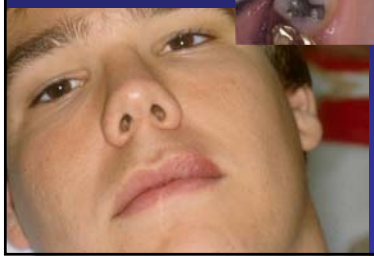

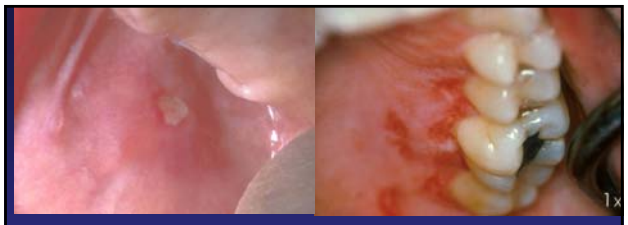

Aphthous Ulcer vs HSV

Prodrome	sometimes	usually
Duration	10-14 days	10-14 days
Location	Nonkeratinized - buccal mucosa, ventral tongue, soft palate	Keratinized – gingiva, lip, hard palate

Aphthae Treatment

Dexamethasone elixir 0.5 mg/5ml

Dispense 500 ml

Sig: 1 tsp quid; hold for 3 mins, spit out, no food or liquid for 30 mins

For easy to reach spots like lips can use a topical steroid such as Lidex gel or cream or more potent steroid like Clobetasol.

Treatment for Aphthae

Intralesional steroid injection- about 0.3-0.5 cc of 40mg/cc triamcinolone diacetate

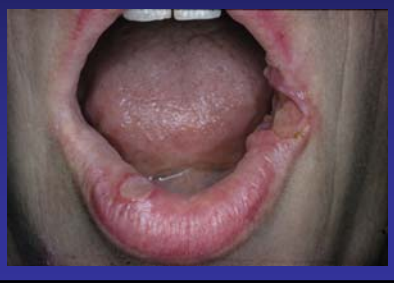

Recurrent HSV Treatment

Take at onset of symptoms:

- RX: Famciclovir 500 mg (Famvir)
- Disp: 3
- Sig: 3 tablets at first sign of symptoms
- RX: Valacyclovir 1 gm (Valtrex)
- Disp: 4
- Sig: Take 2 tablet bid

Primary Herpetic Gingivostomatitis

- In the US, 70-90% of adults have antibodies to HSV-1.
- Highest incidence of HSV-1 occurs in children aged 6 months to 3 years.
- 99% of affected individuals undergo a subclinical infection – in children may be confused with eruption gingivitis
- 1% of individuals develop full-blown primary herpetic gingivostomatitis: ⇑ temp, regional lymphadenopathy, difficulty eating

Treatment for Primary HSV-1

RX:
Acyclovir 400 mg
Disp: 32 capsules
Sig: 2 capsules tid for the first 3 days then 1 capsule bid for 7 days

RX:
Famvir 500 mg
Disp: 20 tablets
Sig: 1 tablet bid for 10 days

Traumatic Ulcerative Granuloma (with stromal eosinophils) TUGSE

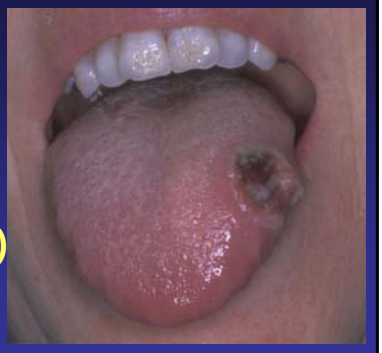

Traumatic Granuloma

- Synonyms: Traumatic ulcerative granuloma with stromal eosinophilia (TUGSE), traumatic ulcer.
- A histopathologically unique mucosal ulceration
- Usually see an adjacent source of irritation
- Many cases exhibit a deep pseudoinvasive inflammatory reaction which is slow to resolve mimicking early SCC

Traumatic Granuloma

- Male predominance and occurs in people of all age ranges.
- Tongue most common location
- Has been reported on the gingiva, buccal mucosa, floor of mouth, palate, and lip.
- Duration is of 1 week to several months

Traumatic Granuloma

- **Microscopic findings:**
- Fibrinopurulent membrane of variable thickness
- Ulcer bed composed of granulation tissue with acute and chronic inflammatory cells.
- The infiltrate extends into the deeper tissues, including striated muscle composed of sheets of benign histiocytes intermixed with eosinophils.

Traumatic Granuloma Treatment

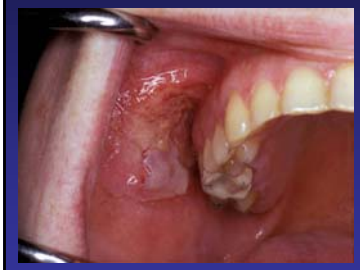

- First determine if it is traumatic and not SCC
- Intralesional steroid injection-about 0.3-0.5 cc of 40mg/cc triamcinolone diacetate (*Aristicort*)
- This may need to be repeated 1-3x

Therapeutic Agents
Susan Müller, DMD, MS
September 30, 2013

A. Candidiasis

Mouthrinse

RX: Nystatin oral suspension 100,000 units/ ml
Disp: 280 ml
Sig: 1 tsp, qid, hold for 3 mins, expectorate, no food/liquid/rinsing for 30 mins

Note: If the patients wear dentures, these must be removed before rinsing

Ointments/Creams

RX: Nystatin ointment 100,000 units/gram (Mycostatin)
Disp: 30 gm
Sig: Apply thin film to inner surfaces of dentures and angles of mouth 2-4 times a day

RX: Ketoconazole 2% cream (Nizoral) or Clotrimazole 1% cream (Lotrimin-Rx)
Disp: 30 gm
Sig: same as for ointment

**RX: Nystatin and triamcinolone acetonide (Ointment or cream)
Disp: 30 gm
Sig: Apply to corner of mouth bid

***Note: This is good for angular cheilitis, particularly when there is an inflammatory component. The steroid quickly reduces the inflammation*

Lozenges

RX: Clotrimazole 10 mg (Mycelex oral troches)
Disp: 70 troches
Sig: Dissolve in mouth 5 tabs per day. NPO 30 mins

Note: Patients need to remove dentures before using the troche to ensure the medication reaches the mucosa underneath the denture

Systemic Treatment

RX: Fluconazole 100mg (Diflucan)
Disp: 14
Sig: 1 tab qd
Note: Be aware of possible drug interactions with: ***warfarin, statins, oral hypoglycemic;*** *may need a 4 week course*

B. Recurrent Oral Herpes Infection

Topical

RX: Acyclovir 5% ointment (Zovirax)
Disp: 15 gm
Sig: Apply hourly at the onset of symptoms

RX: Pencyclovir 1% cream (Denavir)
Disp: 2 gm
Sig: Apply every 2 hrs during waking hrs for 4 days at the onset of symptoms

Systemic

RX: Acyclovir 400mg (Zovirax)
Disp 10 capsules
Sig: 1 capsule bid at onset of symptoms for 3-5 days.

RX: Famciclovir 500 mg (Famvir)
Disp: 3
Sig: 3 tablets at first sign of symptoms

RX: Valacyclovir 1 gm (Valtrex)
Disp: 20
Sig: Take 1 tablet bid for 3 days

Note: Use all systemic HSV medications with caution when prescribing to patients with impaired renal function

C. Primary Herpes Simplex Infection

RX: Famciclovir 500mg (Famvir)
Disp: 20 tablets
Sig: 1 BID for 10 days

RX: Acyclovir 400 mg (Zovirax)
Disp: 32 capsules
Sig: 2 capsules TID for the first 3 days, then 1 capsule bid for 7 days

D. Ulcers, including Erosive Lichen Planus, Mucous Membrane Pemphigoid, Aphthous Stomatitis, and Traumatic Ulcers.

Topical Agents

RX: Fluocinonide 0.05%% (Lidex) or Clobetasol 0.05% (Temovate) (depending on where you use it prescribe gel or cream)
Disp: 30 gm
Sig: Apply to affected area BID

Note: Please let patients know that the packaging says that the product cannot be used in the mouth, but that it is okay to use

Mouthrinse

RX: Dexamethasone elixir 0.5mg/5ml
Disp: 500 ml
Sig: 1 tsp qid, hold for 3 mins, expectorate, no food/liquid or rinsing for 30 mins

Note: A low alcohol formulation (5%) is available as well, and may be better tolerated by some. You need to specify on prescription:
Roxane Laboratories NDC # 00054-3177-63 NO SUBSTITUTIONS, PLEASE SPECIAL ORDER IF IT IS NOT AVAILABLE

RX: Triamcinolone rinse
Directions to pharmacist:
.96 grams triamcinolone powder with purified water and .24 g saccharin sodium QS to 240 ml to final concentration of 4mg/ml
Sig: 1 tsp qid, hold for 3 mins, expectorate, no food/liquid or rinsing for 30 mins

Systemic

Prednisone 10 mg
Disp:
Sig: 30 mg to 60 mg PO q AM. Sequence depends on disease severity. I often do 60 mg day 1, 50 mg day 2, 40 mg day 3, 30 mg day 4, 20 mg day 5-7, 10 mg day 8-12, then one every other day for 2 or 3 more doses.

Note:
a. Prednisone should be taken within 1½ hours after normal waking time to minimize side-effects
b. Candidasis can be a side-effect of any steroid or antibiotic therapy, either topical or systemic.
c. Diabetic patients need to monitor glucose levels carefully since prednisone increases blood glucose concentrations.

Intralesional Steroids

RX: Triamcinolone acetonide injectable 40 mg/ml
Area should be anesthetized before injection
Inject 10-40 mg (I use a 1 cc TB syringe and inject generally .5 cc or 20 mg)
Useful in solitary major aphthous ulcers and traumatic ulcers

Anticollagenase Agents for Desquamative Gingivitis

RX: Doxycycline 50mg or 100mg
Disp: 60
Sig: Take one tablet BID

Note: Usually the doxycycline medication is used for the initial 2-6 months of treatment and then topical steroids are use for maintenance.

Important: *Remember that doxycycline may decrease the effectiveness of birth control pills, so those patients will need supplemental birth control. Also, remember to warn about possible photosensitivity.*

D. Burning Mouth Syndrome

RX: Clonazepam 0.5 mg
Disp: 30 tablets
Sig: ½ tab PO PM, if not change after 7 days, then 1 tab PM

It is important to let the patient know that this medication just decreases the problem, not cure the problem. They usually still have the burning, but it is more tolerable. Evaluate after 30 days. Depending on the circumstances, I will slowly increase to 1 mg.

If the patient is unable to take Clonazepam, or the drug is suboptimal I use alone or in combination with a tricyclic antidepressant:

RX: Amitriptyline 25 mg
Disp: 30 tablets
Sig: 1 tablet PO at bedtime, advancing as directed, this medication can be increased to 50 mg over time.

OR
**RX: Nortriptyline 10 mg
Disp: 30 capsule
Sig: 1 capsule PO at bedtime, advancing as directed

***Note: causes less drowsiness and xerostomia and may be better tolerated than amitriptyline in the elderly*

OTC Therapy
Alpha Lipoic Acid
600 mg daily
200 mg three times a day with meals

Capsaicin rinses
Few drops of Tabasco in teaspoon of H20, swish and spit
Thought to work by deadening nerve receptors

Xerostomia

Pilocarpine 5mg (Salagen)
Sig: 1 tab TID, may increase to 1 tab QID

Cevimelime (Evoxac) 30 mg capsules
Sig: 1 tab TID

Note: Important to remind patients to drink plenty of water! It may take up to 3 months to achieve optimal results.